

Biliary Atresia

Anna M. Banc-Husu, MD

Division of Gastroenterology, Hepatology and Nutrition | Ann & Robert H. Lurie Children's Hospital of Chicago | 225 East Chicago Avenue, Chicago, IL 60611

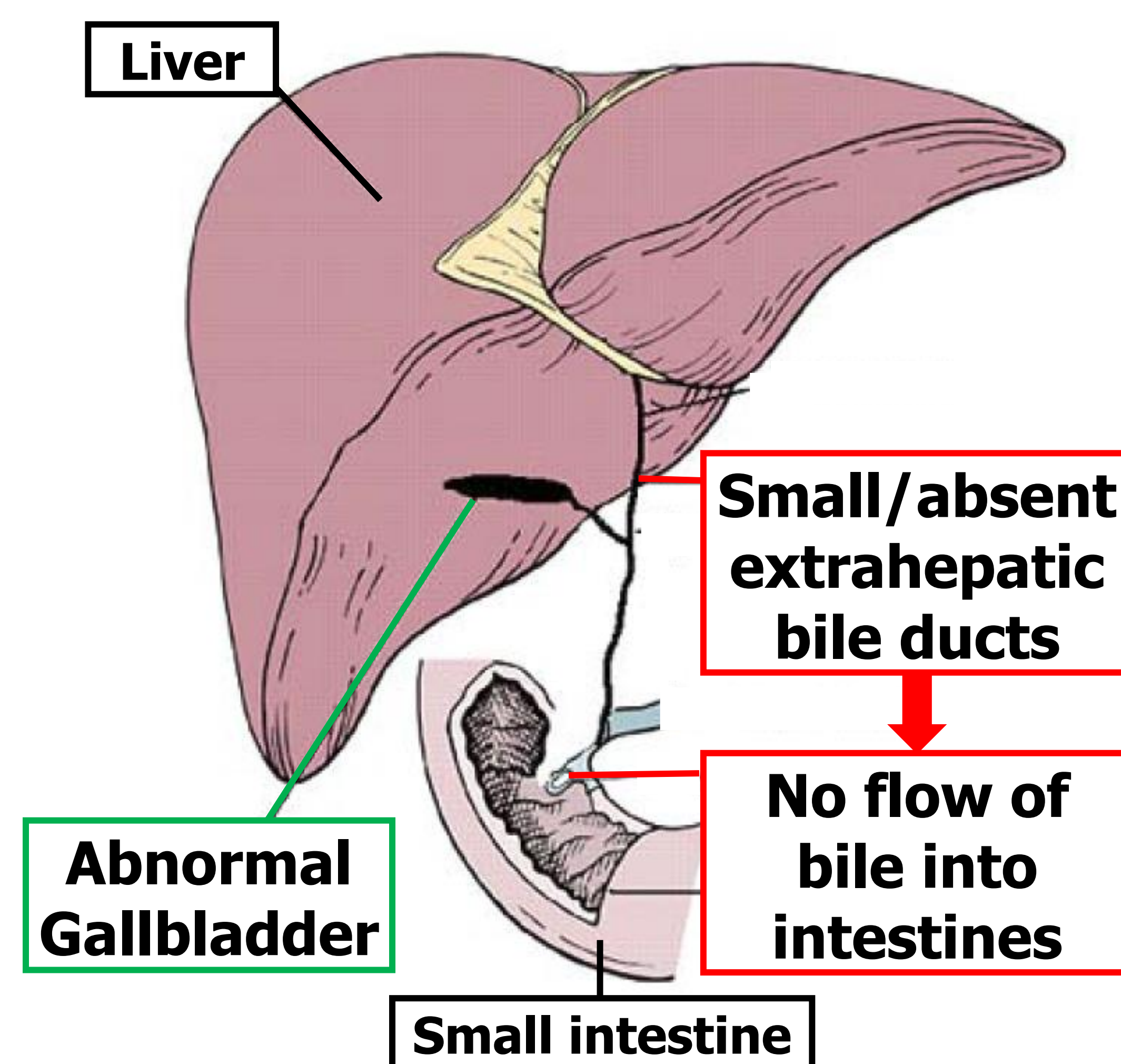
Ann & Robert H. Lurie
Children's Hospital of Chicago®

Northwestern Medicine®

Feinberg School of Medicine

What is biliary atresia?

- Biliary atresia (BA) is a liver disease of infancy that is the leading cause of pediatric liver transplantation.
- Biliary atresia is characterized by destruction of the bile ducts both inside and outside of the liver.
 - **Bile ducts** normally carry bile from the liver to the gallbladder, and eventually into the intestines.
 - **Bile** is composed of waste and other products necessary for digestion and absorption of nutrients. It's accumulation in the liver is toxic.
- In biliary atresia, these bile ducts are damaged leading to accumulation of bile, damage to the liver cells, and eventual scarring of the liver called cirrhosis.



Who is affected by biliary atresia?

- Biliary atresia occurs in infants less than 3-4 months of age.
- It is a rare disease and occurs in 1 in 12,000 live births in the United States per year.
- Up to 10-20% of infants with biliary atresia may have other associated malformations including multiple spleens, abnormal vessels supplying or draining the liver, or heart defects.
- No specific risk factors have been identified.

What causes biliary atresia?

- The cause of biliary atresia is unknown.
- Research is currently underway to find the exact cause of biliary atresia. Several explanations exist including:
 - Some trigger (possible virus or environmental toxin) causes one's own immune system to attack 'self' components of the bile ducts
 - Abnormalities in the formation and organization of the bile ducts early on in development
 - Predisposing genetic factors

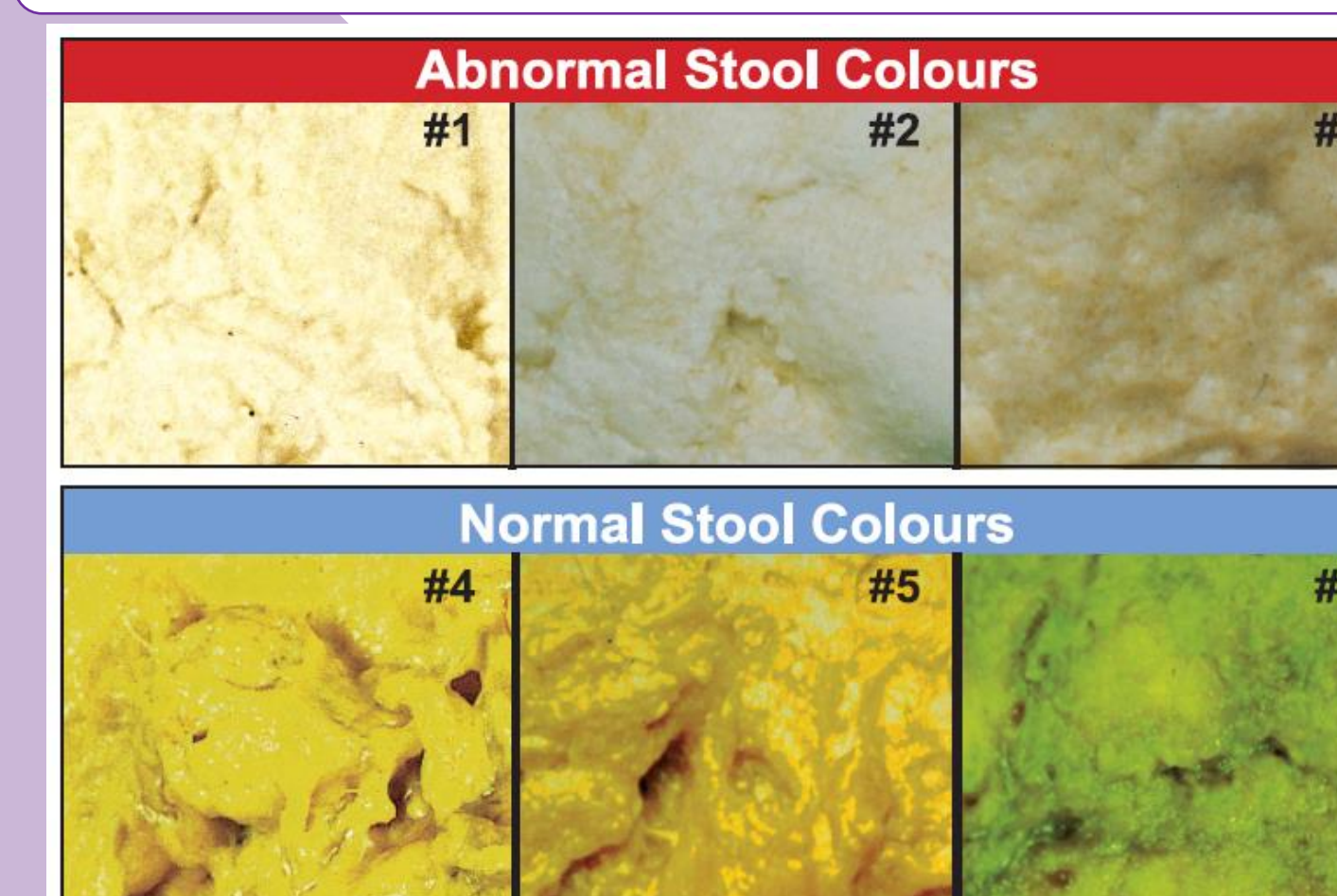
How is biliary atresia diagnosed?

- BA is diagnosed early in infancy.
- Combination of clinical, laboratory, and radiological studies
- Stool color is a key to early detection.

Clinical Presentation

- No symptoms at birth
- **By 2-6 weeks of age:**
 - Yellowing of the skin
 - Pale stools
 - Large liver and spleen
 - Abnormal liver tests

Stool Color Card

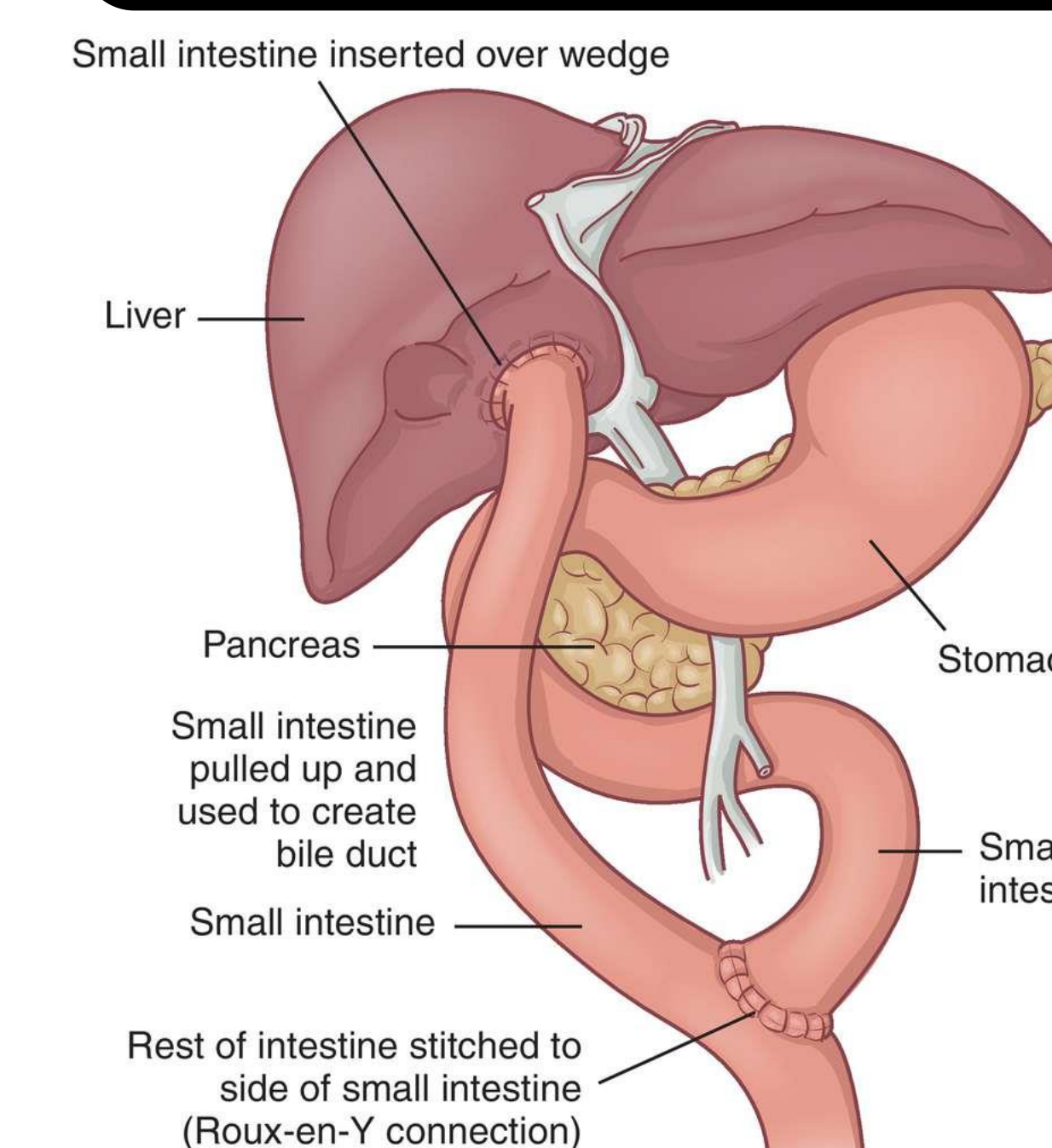


Additional Diagnostic Studies

- **Ultrasound (US)**
 - May show absent gallbladder
 - But, up to 20% of patients may have a normal US
- **Hepatobiliary scintigraphy (HIDA Scan)**
 - Checks for excretion of bile from liver into the intestines
- **Liver Biopsy**
 - Characteristic findings of bile duct obstruction
- **Intraoperative Cholangiogram**
 - Injection of the bile ducts with contrast in the operating room to watch for drainage into intestines

How is biliary atresia treated?

Kasai Procedure (hepatportoenterostomy)



(McCance and Huether, Pathophysiology: the biologic basis for disease in adults and children, 2010)

- Blocked bile ducts are removed and a piece of small intestine is connected to the liver to allow direct flow of bile from the liver.
- Best outcome if performed before 45 days of life.
- If performed after 3 months of age, only 25% of infants will have successful drainage of bile.

Liver Transplantation

- Up to 80% of patients ultimately require a liver transplant due to progression and complications of end-stage liver disease, such as GI bleeding, ascites (increased abdominal fluid), worsening jaundice, and poor growth.
- Only 25% of patients with a Kasai procedure will survive into their 20s without requiring a liver transplant.
- Long-term survival after liver transplantation is over 90%, similar to children receiving a liver transplant for other reasons.

Improving patient outcomes

- Early diagnosis is critical for a successful Kasai procedure.
- Biliary atresia cannot be prevented as there still is no clear cause of the disease.
- Ongoing research to improve outcomes:
 - Screening programs using stool color cards has led to earlier detection and improved outcomes
 - Identifying the exact cause of biliary atresia can lead to earlier diagnostic screening tests and new treatment strategies